

Long-term outcomes of transvestibular vaginoplasty with pelvic peritoneum in 182 patients with Rokitansky's syndrome

Jian-Hong Zhou, M.D., Ph.D., Jin Sun, M.D., Cun-Bo Yang, M.D., Zhen-Wei Xie, M.D., Ph.D.,
Wen-Qun Shao, M.D., and Hang-Mei Jin, M.D.

Department of Gynecology, Women's Hospital, School of Medicine, Zhejiang University, Zhejiang, People's Republic of China

Objective: To evaluate the technical feasibility and anatomical and functional outcomes of one-stage transvestibular vaginoplasty with pelvic peritoneum for the patients with Mayer-Rokitansky-Kuster-Hauser (MRKH) syndrome.

Design: A retrospective review of prospectively collected data.

Setting: A university hospital.

Patient(s): A total of 182 women with MRKH syndrome.

Intervention(s): Undergoing transvestibular vaginoplasty with pelvic peritoneum.

Main Outcome Measure(s): The perioperative results, complications, and anatomical and functional outcomes of transvestibular vaginoplasty with pelvic peritoneum.

Result(s): The mean operative time was 72.2 minutes (range 55–150 minutes). Average blood loss was 78.5 mL (range 40–170 mL). The only perioperative complication was one case of rectal-vaginal fistula. Thirty-four patients had vault granulation at the neovagina, which healed after trimming and the mean length of the neovagina was 9 cm (range 7–12 cm) without any shrinkage at the follow-up of 3 months after operation. The neovaginal introitus admitted two fingers in width in all patients. Good functional outcomes were found in the patients at follow-up 15 years after surgery with 80% of the cumulative proportion of sexual satisfactory activity.

Conclusion(s): Transvestibular vaginoplasty with pelvic peritoneum is an effective and feasible approach for women with MRKH syndrome. The procedure has satisfactory long-term anatomical and functional results. (*Fertil Steril*® 2010;94:2281–5. ©2010 by American Society for Reproductive Medicine.)

Key Words: Neovagina, MRKH syndrome, transvestibular approach, peritoneal vaginoplasty

Mayer-Rokitansky-Kuster-Hauser syndrome (MRKHS) (1–3) is characterized by vaginal agenesis with variable Müllerian duct abnormalities. Women who suffer from MRKH have no vagina or uterus but normal karyotype (46, XX), ovarian function, external genitalia, and secondary sex characteristics of female gender.

The management of vaginal agenesis as found in MRKH syndrome constitutes a significant challenge as its outcome affects both the physical and psychosocial health of the women (4). Great efforts have been made to improve the outcome of constructing an artificial vagina, for which many techniques have been described, including nonoperative methods such as progressive dilation (5) and surgical options such as skin transplants (6, 7), intestinal transplants (8, 9), myocutaneous transplants, and epithelialization from the outer skin layer (the Vecchiotti method). However, at present no standard treatment exists (10). In addition, most of these procedures require laparotomy, resulting in a lesser cosmetic appearance. In addition, these operations are extensive and time-consuming and involve a transperitoneal as well as perineal approach. For these reasons attempts have been made to reduce

the invasiveness of vaginal reconstruction. The technique using peritoneum from the pouch of Douglas, originally described by Rothman (11) and subsequently modified by Tamaya and Imai (12) achieves most of these goals but still requires a laparotomy. On the basis of this technique, we developed a one-stage transvestibular vaginoplasty using pelvic peritoneum, either with laparoscopic assistance or with a laparotomy. In this article we describe the details of this technique and the long-term results of the anatomical structure and function of a neovagina.

MATERIALS AND METHODS

Patients and Preoperative Care

From January 1990 to December 2006, 182 women diagnosed MRKH syndrome underwent transvestibular vaginoplasty with pelvic peritoneum at Women's Hospital, School of Medicine, Zhejiang University. Preoperative assessment of the patients included counseling, physical examination, ultrasound of the pelvic abdominal region, a female hormonal profile, and IV urography to exclude associated urological anomalies (4). All women were provided adequate counseling on the advantages and disadvantages of the nonsurgical technique (Frank's method) and surgical techniques (Vecchiotti's method, McIndoe's method, Williams's technique, and transvestibular vaginoplasty with pelvic peritoneum), and all patients were encouraged to try Frank's method using dilator, but the transvestibular vaginoplasty with pelvic peritoneum was their final choice. Institutional review board (IRB) approval was obtained.

Preoperative preparation consisted of a thorough bowel preparation, which included 2 days of a low-residue semifluid diet and 1 day of fasting. A cleaning enema was added on the day before surgery.

Received September 17, 2009; revised January 16, 2010; accepted February 2, 2010; published online March 19, 2010.

J.-H.Z. has nothing to disclose. J.S. has nothing to disclose. C.-B.Y. has nothing to disclose. Z.-W.X. has nothing to disclose. W.-Q.S. has nothing to disclose. H.-M.J. has nothing to disclose.

Reprint requests: Hang-Mei Jin, M.D., Department of Gynecology, Women's Hospital, School of Medicine, Zhejiang University, 2 Xueshi Road, Hangzhou, Zhejiang, 310006, People's Republic of China (FAX: 86-571-87061878; E-mail: jinhm@zju.edu.cn).

Although there is no standard method to evaluate the peritoneum before surgery, we always performed a rectal examination preoperatively to assess the relative position of the cul-de-sac peritoneum. The peritoneum is classified into three types as follows: type I, the cul-de-sac peritoneum was easily touched; type II, the cul-de-sac peritoneum was just touched; and type III, the cul-de-sac peritoneum was not touched (Fig. 1).

One-stage Transvestibular Vaginoplasty With Pelvic Peritoneum

The patient was placed in the dorsal lithotomy position under epidural anesthesia. A 5-cm transverse incision was made at the perineum about 1 cm below the posterior fourchette. Two fingers dissected the space beneath the urethra and the rectum upward and laterally (Fig. 2A). The space between the rectum and the urethra, as well as the bladder, was dissected and identified by blunt technique with two fingers upward just beneath the urethra and bladder to the level of the cul-de-sac peritoneum (Fig. 2B). The peritoneum was detached by blunt dissection as described by Rothman (11). Then the space was exposed by retractors 12 cm anteriorly and posteriorly as well as upward by pulling on the retractors. The posterior tissues of the pelvic peritoneum were bluntly dissected to the bulging posterior wall of the pelvic peritoneum. The pelvic peritoneum was confirmed and opened transversely by scissors to a length of 4–5 cm (Fig. 2C). If rudimentary uterine tissue was present and was interfering with the peritoneal dissection, it could easily be freed from the peritoneum and removed.

The pelvic peritoneum was then gently stripped from the rectum posteriorly, the bladder anteriorly, and also from the pelvic side wall. The edges of the opened pelvic peritoneum reached the mucosa of the introitus, to which they were sutured (Fig. 2D). The vaginal space covered with the pelvic peritoneum was transperineally exposed by retractors anteriorly and posteriorly. The top of the reconstructed vagina was formed by closing the pelvic peritoneum at a level to make the vagina as long as possible (Fig. 2E). A soft mold was inserted into the neovagina (Fig. 2F). We used a mold of iodoform gauze covered with two condoms that was pressed in place to the vulva by a home-made tape.

Postoperative Care

Broad spectrum antibiotics were given IV 5–7 days after surgery. The soft vaginal mold and Foley catheter were kept in place for 7 days. Patients were then encouraged to practice vaginal mold removal and insertion every day and advised to keep the mold in situ at all times in the first 3 months. If the women had regular sexual intercourse (twice or more a week) 3 months after the surgery, the mold was removed; otherwise, the mold should be kept in the neovagina at night.

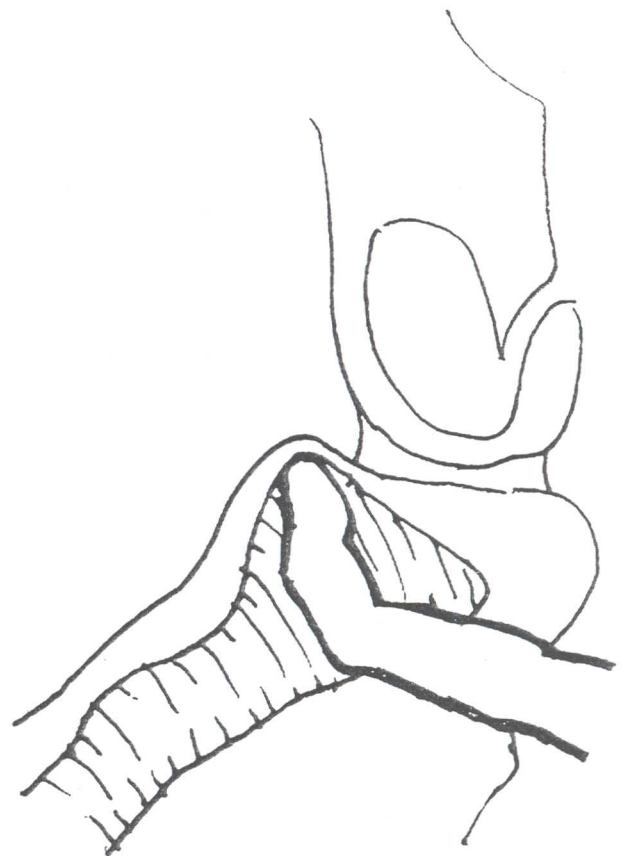
All women were followed up at 2 weeks, 3 months, and 6 months after the surgery. Yearly follow-up was arranged thereafter. The width, length, and stenosis of the neovagina was examined and recorded. The width of the neovagina, defined as the level distance between the right and left edge of the introitus and its length, defined as the straight distance from introitus to the top of the neovagina, were measured by speculum. The neovagina stenosis was defined as admitting less than two fingers. The modified sexual activity questionnaire was used to evaluate the functional results of the surgery (including vaginal discharge and possibility of intercourse) and the quality of intercourse (including frequency of intercourse, lubrication of the neovagina, difficulties with penetration, and ability to achieve orgasm) (13). The questionnaire was mailed to each woman and asked to be completed anonymously and placed it into a mailbox when visiting hospital for follow-up. Intercourse was considered satisfactory if there is no dyspareunia, no need for lubricants, and occurrence of orgasm, although not consistently.

RESULTS

The average age was 23 years (range 19–35 years) and average height was 157 cm (range 150–171 cm). Sixty-two (34.1%) patients were married. Sixty-three (34.6%) patients complained severe dyspareunia and 119 (65.4%) complained of primary amenorrhea.

FIGURE 1

Rectal examination to roughly assess the relative position of the cul-de-sac peritoneum.



Zhou. Vaginoplasty for women with MRKH syndrome. *Fertil Steril* 2010.

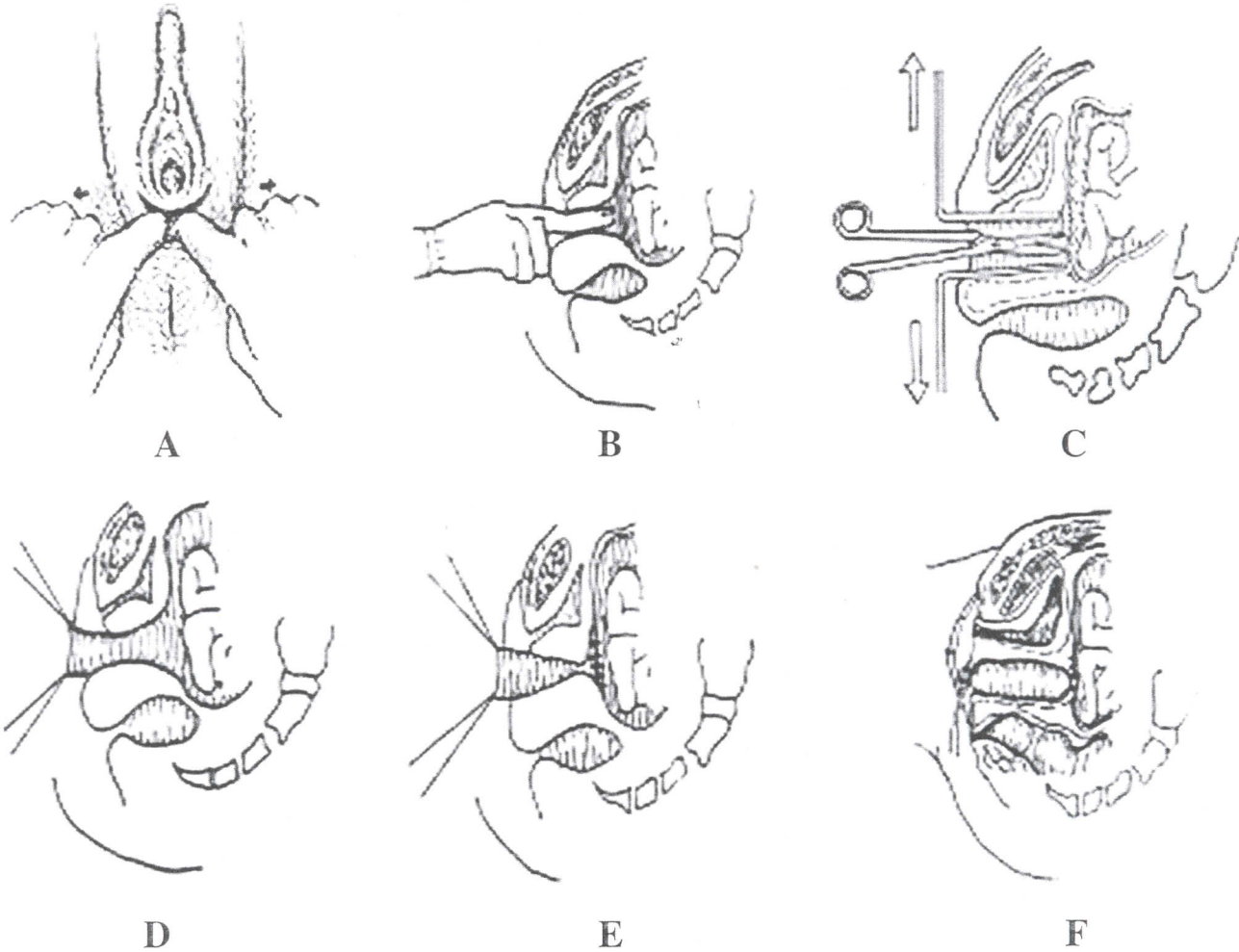
All the women had normal karyotype (46, XX), ovarian function, normal secondary sexual characteristics, typically female hair distribution, and normal vulvar development. A total of 138 women had no vagina and 44 had an approximately 1 cm deep depression at the vaginal opening. A total of 112 women had type I peritoneum, 44 type II, and 26 type III. All women had a rudimentary uterus with normal size ovaries.

Intravenous urography showed kidney anomalies in 17 patients, including absence of the left kidney in 5, absence of the right kidney in 3, polycystic kidney in 4, renal duplication in 3, and pelvic ectopic kidney in 2. A roentgenogram showed skeletal anomalies in 16 patients, including scoliosis in 6, torticollis in 4, absence of a rib in 2, polydactyly in 3, and malformation of phalanges of toes in 1 patient.

One-stage transvestibular vaginoplasty with pelvic peritoneum was successfully performed without a laparotomy or laparoscopic assistance in 160 women including 111 of 112 women with type I peritoneum, 38 of 44 with type II peritoneum, and 11 of 26 with type III peritoneum. Transvestibular abdominal vaginoplasty with pelvic peritoneum was conducted in 22 women including 1 of 112 with the type I peritoneum, 6 of 44 patients with the type II peritoneum, and 15 of 26 patients with the type III peritoneum. Average operation time was 70.2 minutes (range 55–150 minutes). Average hospital stay was 7 days (range 5–9 days) after operation. Average

FIGURE 2

(A) A 5-cm transverse incision was made in the perineum about 1 cm below the posterior fourchette. Two fingers dissected the space beneath the urethra and the rectum upward and laterally. (B) The space between the rectum and the urethra and bladder was dissected and identified by blunt technique to the level of the cul-de-sac peritoneum. (C) The pelvic peritoneum was confirmed and opened transversely with scissors. (D) The edges of the opened pelvic peritoneum reached the mucosa of the introitus, to which they were sutured. (E) The top of the reconstructed vagina was formed by closing the pelvic peritoneum. (F) A soft mold was inserted into the neovagina.



Zhou. Vaginoplasty for women with MRKH syndrome. *Fertil Steril* 2010.

hemorrhage was 78.5 mL (range 40–170 mL). Rectal injury occurred in seven women including two with type II peritoneum and five with type III peritoneum. In all cases, injuries were recognized and repaired immediately intraoperatively using a two-layer closure with 3/0 absorbable thread without drain placement. No early postoperative complications were found. A rectal-vaginal fistula occurred in one woman and healed well 3 months after repair. No bladder injury occurred.

Thirty-four women had vault granulation at the neovagina that healed completely after trimming. The mean length of the neovagina was 9 cm (range 7–12 cm), with two fingers in width in all women 3 months after surgery.

The Kaplan-Meier procedure was used to evaluate the long-term functional outcome of surgery. It was found that all patients had a well-formed neovagina 9 cm in average length and two fingers in width at follow-up 1 year after surgery and the cumulative proportion of sexual satisfactory activity was 100%. Good functional out-

comes were found in the patients at follow-up 15 years after surgery with 80% of the cumulative proportion of sexual satisfactory activity (Table 1).

DISCUSSION

Several methods have been reported to create a neovagina, including a nonsurgical technique (Frank's method) and numerous surgical techniques (Vecchiotti's method, McIndoe's method, Williams's technique, and their modifications) (14–18). There is no consensus on the best option for surgical correction of the vaginal agenesis associated with the MRKH syndrome (19). The optimal reconstructive procedure should create a vagina of appropriate length that is achieved in a one-stage surgery using a simple surgical technique that is reliable and least morbid. In addition it would be ideal that the procedure leaves no scar, does not narrow, and provides

TABLE 1

Long-term functional results of 182 patients after surgery (Life Table).

Follow-up time (y)	Cases of follow-up (N)	Length of neovagina (x ± s) (cm)	Cumulative proportion of satisfactory sexual activity
1	182	8.50 ± 1.53	1.0
3	158	7.68 ± 1.63	0.98
5	123	7.82 ± 1.39	0.96
10	67	7.88 ± 1.65	0.88
15	15	8.22 ± 2.11	0.80

Zhou. Vaginoplasty for women with MRKH syndrome. Fertil Steril 2010.

a satisfactory cosmetic result while leaving the external genitalia intact (10).

Frank's method involves a gradual increase in the size of glass dilators progressively invaginating into the mucosa dimple at the vestibule beneath the urethra (5). Originally described by Frank in 1938, this technique used graduated vaginal dilators to create a vagina or augment an existing structure that was inadequate for sexual intercourse. Patients are required to apply pressure on the perineal dimple with graduated dilators for approximately 30 minutes per day. The first prospective study of vagina dilation demonstrated that it is possible to create a vagina of normal length and to improve sexual confidence (20). However, there are some disadvantages to dilators. Women may find them uncomfortable and unpleasant and report that dilation acts as a constant reminder of the abnormality (21). Contemporary alternatives, such as vibrators, have been suggested to improve compliance of this technique in younger patients.

For those women in whom dilation does not work or is not possible surgical construction is necessary. Numerous forms of vaginoplasty have been developed. The most commonly used procedures create a neovaginal space that was lined with either a split thickness skin graft (the McIndoe-Reed procedure) or a section of intestine.

A major disadvantage of the McIndoe technique is the formation of visible scars at the origin of the skin graft site, which is usually unacceptable to young women, and the end result is a dry vagina. In addition, failure to comply with follow-up dilator treatment can result in vaginal stenosis.

The colon has gained in popularity, particularly with pediatric surgeons. However, it is not free from problems. Excessive mucous discharge, dyspareunia, introital stenosis, and prolapse of the mucosa have all been reported (22). In addition, the neovagina retains the intestinal type of lining, which is not ideal and is at high risk of bowel complications such as colorectal fistula, mechanical bowel obstruction, stenosis of the anastomosis, and diversion colitis (8,

23). A laparotomy is necessary, although laparoscopic techniques were described recently (24, 25). These procedures should not be used as a first-line treatment for vaginal agenesis.

Rothman described for the first time a vaginoplasty using pelvic peritoneum (11) that was modified later (12). Laparotomy was done to assess the peritoneum and to close the cranial end of the neovaginal vault during the surgery. The peritoneal flap technique has several distinct advantages. There is no danger of flap necrosis or lack of graft take, which are potential problems with any other transferred flap or graft. The reconstructed vagina has a natural axis suitable for sexual intercourse. The peritoneum has great regenerative powers and can undergo squamous metaplasia when exposed to the outside (11, 26). The metaplastic changes induce a stable reconstruction, free from contracture. The peritoneal lining does not carry much fat, a distinct advantage in the long term compared with skin flaps, in which the mandatory layer of fat may increase with obesity, thus crowding the vagina. Maintenance of hygiene is simple and odor is not a problem as it is with skin grafts. Obviously, there will never be a problem of hair growth. There is no donor site scarring, a distinct advantage in this young population of patients with already fragile self-image.

We have developed a one-stage transvestibular vaginoplasty with pelvic peritoneum, without a laparotomy or laparoscopic assistance in most cases since 1985. During the past 20 years, more than 200 patients have undergone this procedure. The operative time varies between 55 and 150 minutes and the postoperative complications are rare. Our modified technique is a quite simple and a quick surgical procedure that allows for the creation of a functioning neovagina. The neovagina is two-finger in width and 7–12 cm in length, which is pink, clean, moist, and expandable, with satisfactory sexual function. It is found that the neovagina epithelium has squamous metaplastic changes from the peritoneum and its secretions are acidic by colposcopy. Vault granulation is a small problem in some of the cases. The vaginal mold should be inserted before the patient has regular sexual intercourse. Thus, we believe that the procedure is a safe and reasonable choice for patients with vaginal agenesis with acceptable complications and satisfactory results. It offers a high success rate and reduces morbidity compared with the classic available procedures, especially for the patients with type I and type II peritoneum. For those with type III peritoneum, it is better to undergo a transvestibular abdominal vaginoplasty with pelvic peritoneum with the assistance of a laparotomy or laparoscopy to secure satisfactory results and rare complications.

In conclusion, transvestibular vaginoplasty with pelvic peritoneum is feasible for women with MRKH syndrome. The surgery is safe and effective when it is performed by surgeons with experience in pelvic floor reconstruction. All the neovaginas had adequate length, showed no shrinkage during follow-up, and gave good functional results.

Acknowledgments: The authors thank Sam Siddighi, M.D., Chief of Female Pelvic Medicine & Reconstructive Surgery of Loma Linda University School of Medicine, for his excellent instruction to this article.

REFERENCES

- Mayer CA. J Über verdoppelungen des uterus und ihre arten nebst bemerkungen über hasenscharte und wolfsrachen. *J Chir Auger* 1829;13: 525.
- Küster H. Uterus bipartitus solidus rudimentarius cum vagina solida. *Zeitschrift für Geburtshilfe und Gynäkologie*. Stuttgart 1910;67:692–718.
- Hauser GA, Schreiner WE, Mayer-Rokitansky-Kuester syndrome. Rudimentary solid bipartite uterus with solid vagina. *Schweiz Med Wochenschr* 1961;91:381–4.
- Golan A, Langer R, Bukovsky I, Caspi E. Congenital anomalies of the müllerian system. *Fertil Steril* 1989;51:747–55.
- Frank RT. The formation of an artificial vagina without operation. *Am J Obstet Gynecol* 1938;35: 1053–5.
- Adamson CD, Naik BJ, Lynch DJ. The vacuum expandable condom mold: a simple vaginal stent for McIndoe-style vaginoplasty. *Plast Reconstr Surg* 2004;113:664–6.

7. McIndoe A. The treatment of congenital absence and obliterative conditions of the vagina. *Br J Plast Surg* 1950;2:254-67.
8. Hendren WH, Atala A. Use of bowel for vaginal reconstruction. *J Urol* 1994;152:752-5 [discussion: 756-7].
9. Parsons JK, Gearhart SL, Gearhart JP. Vaginal reconstruction utilizing sigmoid colon: complications and long-term results. *J Pediatr Surg* 2002;37:629-33.
10. Hensle TW, Chang DT. Vaginal reconstruction. *Urol Clin North Am* 1999;26:39-47.
11. Rothman D. The use of peritoneum in the construction of a vagina. *Obstet Gynecol* 1972;40:835-8.
12. Tamaya T, Imai A. The use of peritoneum for vaginoplasty in 24 patients with congenital absence of the vagina. *Arch Gynecol Obstet* 1991;249:15-7.
13. Thirlaway K, Fallowfield L, Cuzick J. The Sexual Activity Questionnaire: a measure of women's sexual functioning. *Qual Life Res* 1996;5:81-90.
14. Schätz T, Huber J, Wenzl R. Creation of a neovagina according to Wharton-Sheares-George in patients with Mayer-Rokitansky-Küster-Hauser syndrome. *Fertil Steril* 2005;83:437-41.
15. Vecchiotti G. Creation of an artificial vagina in Rokitansky-Küster-Hauser syndrome. *Atual Ostet Ginecol* 1965;11:131-47.
16. McIndoe AH, Banniser JB. An operation for the cure of congenital absence of the vagina. *J Obstet Gynaecol Br Emp* 1938;45:490-4.
17. Williams EA. Congenital absence of the vagina: a simple operation for its relief. *J Obstet Gynaecol Br Commonw* 1964;71:511-2.
18. Creatsas G, Deligeorgiou E, Makrakis E, Kontoravdis A, Papadimitriou L. Creation of a neovagina following Williams vaginoplasty and the Creatsas modification in 111 patients with Mayer-Rokitansky-Küster-Hauser syndrome. *Fertil Steril* 2001;76:1036-40.
19. Laufer MR. Congenital absence of the vagina: in search of the perfect solution. When, and by what technique, should a vagina be created? *Curr Opin Obstet Gynecol* 2002;14:441-4.
20. Ismail-Pratt IS, Bikoo M, Liao LM, Conway GS, Creighton SM. Normalization of the vagina by dilator treatment alone in Complete Androgen Insensitivity syndrome and Mayer-Rokitansky-Küster-Hauser syndrome. *Hum Reprod* 2007;22:2020-4.
21. Liao L, Doyle J, Crouch NS, Creighton SM. Dilator as treatment for vaginal agenesis and hypoplasia: a pilot exploration of benefits and barriers as perceived by patients. *J Obstet Gynaecol* 2006;26:144-8.
22. Templeman CL, Lam AM, Hertweck SP. Surgical management of vaginal agenesis. *Obstet Gynecol Surv* 1999;54:583-91.
23. Toolenaar TA, Freundt I, Wagenvoort JH, Huikeshoven FJ, Vogel M, et al. Bacterial flora of the sigmoid neovagina. *J Clin Microbiol* 1993;31:3314-6.
24. Ota H, Tanaka J, Murakami M, Murata M, Fukuda J, et al. Laparoscopy-assisted Ruge procedure for the creation of a neovagina in a patient with Mayer-Rokitansky-Küster-Hauser syndrome. *Fertil Steril* 2000;73:641-4.
25. Cai B, Zhang JR, Xi XW, Yan Q, Wan XP. Laparoscopically assisted sigmoid colon vaginoplasty in women with Mayer-Rokitansky-Küster-Hauser syndrome: feasibility and short-term results. *BJOG* 2007;114:1486-92.
26. Tamaya T, Fujimoto J. Comparison between transabdominal-vulvar and transvulvar approaches for peritoneal vaginoplasty in patients with congenital absence of the vagina. *Eur J Obstet Gynecol Reprod Biol* 1997;72:79-81.